Jurnal Medical Aradean (Arad Medical Journal)
Vol. XVIII, issue 3, 2015, pp. 10-13

PATHOPHYSIOLOGY AND ULTRASOUND ASSESSMENT OF OVARIES IN FIRST TRIMESTER OF PREGNANCY

Furau Cristian[1,2], Furau Gheorghe[1,2], Dascau Voicu[1,2], Cristina Onel[1,2], Ana Liana Tataru[1,2], Dimitriu Mihai[3]

[1] Western University "Vasile Goldis" of Arad, Romania, Obstetrics and Gynecology Department
[2]Emergency Clinical County Hospital of Arad, Romania, Obstetrics and Gynecology Department
[3]"Carol Davila" University of Medicine and Pharmacy Bucharest, Obstetrics and Gynecology Department

ABSTRACT. Ovarian cysts have a very wide reported incidence in literature (0.1-10% of total pregnancies), which is increasing nowadays. We try to assess their incidence in the first trimester of pregnancy in Arad County in the period 2008-2012 and to correlate our findings with possible management options. A total of 1671 patients in their first trimester of pregnancy were evaluated ultrasonographically by obstetricians of the Emergency Clinical County Hospital of Arad, Romania in the period 2008-2012, out of which 1566 corresponded to inclusion criteria. Graph Pad Software and Epi Info 7 were used for statistical analysis. A total number of 313 enlarged ovaries were found (19.99%). Endovaginal ultrasonography was used for 518 cases with reported incidence of 39.96% larger than 3cm ovaries, while for trans-abdominal it was 10.11%. 12.78% of all diagnosed ovarian cysts were surgically treated. Assessment of the ovaries in the first trimester of pregnancy is very important due to high numbers of enlarged ovaries. It represents the key step in early management of ovarian cysts.
KEYWORDS: ovarian cyst, pregnancy, ultrasonography, surgery during pregnancy

INTRODUCTION

Ovarian cysts are a frequent benign pathology that requires surgical treatment in fertile women [1]. First trimester aneuploidy screening or just routine prenatal ultrasound scans can reveal adnexal masses in early pregnancy up to 10% of total pregnancies [Munteanu, 2008, Zanetta G, 2003]. Ovarian tumors rarely cause acute incidents during pregnancy, but careful observation is advised due increasing chances of neoplasm. Ultrasonographic examination in first trimester of pregnancy is a safe method [Maeda K, 2012] and represents a highly sensitive and specific method of diagnosis [Sharma G, 2012]. Although first trimester ultrasound evaluation of the pregnant women should include examination of the adnexa, this is rarely mentioned in obstetric reports.

Normal ovaries have a size of less than 3 x 2 x 2 cm [Kupesic- Plavsic S, 2012]. More than 90% of cysts occurring during pregnancy are non-neoplastic, while corpus luteum usually regresses after 12 weeks of gestation [8]. Serial ultrasound evaluation of non-suspect ovarian cysts is nowadays most frequent management, surgical procedures being reserved for cysts that are increasing considerable their size, for symptomatic cases (in second trimester of pregnancy) or suspicions of malignancy. Ovarian cancer is considered to have a low incidence in pregnancy (1 in 12000-20000 cases), although it is the second most common diagnosed malignancy during pregnancy [Mohomed K, 2006; Hoffman M, 2007].

MATERIALS AND METHODS

A prospective cohort study was designed for assessing the incidence of enlarged ovaries in pregnancy in the Emergency Clinical County Hospital of Arad in the period 2008-2012. Ultrasound examination was performed by obstetricians in our department with competence for obstetric ultrasonography.

Patients were recruited among women that came to our hospital in their first trimester of pregnancy. Informed consent and agreement to complete our studies form were the main inclusion criteria. The other criteria that we had for admission in our study were: age between 15-45 years, pregnancy less than 12 weeks of gestation at first evaluation.

Subjects were examined by endo vaginal ultrasonography if they were less than 7 weeks of gestation following last menses period and if they agreed. Patients between 8-12 weeks of gestation or that haven't agreed for the other method of examination had a trans-abdominal ultrasound performed.

Jurnal Medical Aradean (Arad Medical Journal)
Vol. XVIII, issue 3, 2015, pp. 10-13

We excluded patients that were less than 15 years or older than 45, cases where ovaries couldn't be measured, refusal of the patients to participate in the study or refusal to continue their participation during follow-up.

Graph Pad Software and Epi Info 7 were used for statistical analysis.

RESULTS AND DISCUSSION

The 1566 patients included in the study were distributed as follows: 272 in 2008 (17.37%), 413 in 2009 (26.37%), 414 in 2010 26.43%), 358 in 2011 (22.86%) and 109 in 2012 (6.97%).

Regarding the age groups: 1.66% - 26 cases were between 15-18 years old (consent was signed by another relative as well), 8.17% - 128 cases were between 18-20 years, 21.58% - 338 cases between 21-25, 29.25% - 458 cases between 26-30 years, 23.75% - 372 between 31-35 years and 15.59% - 244 cases were older than 36 years. We observe a higher maternal age compared with general population.

More patients came from sub urban or rural environment (848 cases- 54.15%) compared with the ones coming from an urban environment (718 cases- 45.85%). It was reflected also in education and profession: 14 finished only 4 elementary classes (0.89%), 215 finished 8 classes (13.73%), 682 finished high school (43.55%), while 477 had higher education (30.46%). 1157 patients had a job (73.89%) and 409 (26.11%) were jobless or house-wives.

The distribution of studied pregnancies per year and weeks of gestation is presented in figure 1.

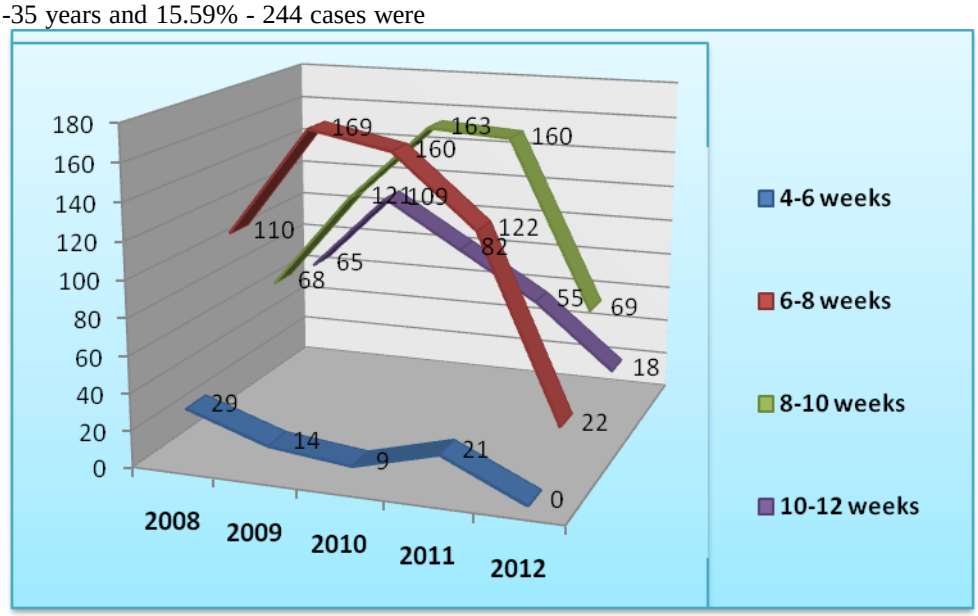

Figure 1: Numerical distribution of pregnancies per weeks of gestation and year

A total of 313 enlarged ovaries were found in our study (19.98%). Endo vaginal examination was performed for 518 patients (33.08%) and 207 enlarged ovaries (L or l higher than 30mm) were found, while for trans-abdominal examination the detection rate was 6.77%.

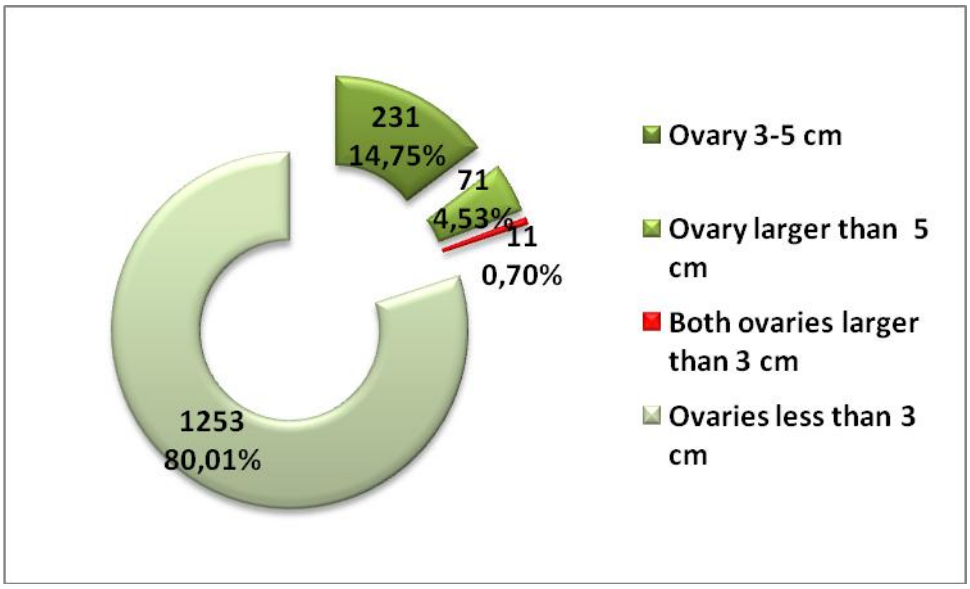

Figure 2: Frequency of ovarian measurement findings (numerical and percentage)

3/5 patients enrolled in our study (60%) that underwent human assisted reproduction techniques had at least one ovary over 30 mm, but none of them needed a surgical procedure.

40 cases needed a surgical management (2.55%).

Our findings concerning enlargement of ovaries in first trimester of pregnancy is higher than in the sources identified in studied literature. We consider that is a consequence of usingendo vaginal transducer and probably of reporting enlarged corpus luteum and of focusing our examination on ovaries. Most of the other authors report a smaller incidence as they are not reporting only first trimester pregnancies. Most of the enlarged ovaries seen, regressed spontaneously.

CONCLUSIONS

Ovarian assessment in the first trimester of pregnancy should be done routinely and written in the examination form of the patient

A high incidence of enlarged ovaries is expected in the first trimester of pregnancy

Most of ovarian cysts regress spontaneously without needing surgical procedure

In emergency cases, or if the size increases between serial examination or in case of suspected malignancy, the surgical procedure should be performed according to existing protocols

REFERENCES

Munteanu Ioan, *Chirurgia endoscopica in ginecologie*, Editura Academiei Romane, 2008

Alpa M Nick, Kathleen Schmeler, Adnexal Masses in Pregnancy, *Perinatology*, Vol 1, No 2, 2012, p13-21

K. Shah, S. Anjurani, V. Ramkumar, P. Bhat, M. Urala: Ovarian Mass In Pregnancy: A Review Of Six Cases Treated With Surgery.*The Internet Journal of Gynecology and Obstetrics*, Vol 14, Number 2, 2011

Zanetta G, Mariani E, Lissoni A, et al, A prospective study of ultrasound in the management of adnexal masses in pregnancy, *BJOG*, 110, 2003, p 578-583

Maeda K: Siguranta utilizarii ultrasunetelor in obstetrica. In: Kurjak AK, Chervenak FA, Vladareanu R: Tratat de ultrasonografie in obstetrica si ginecologie, a treia editie. Bucuresti, Editura Medicala Amaltea, 2012, pp 17-22

Sharma G, Stephen T, Chasen T, Chervenak FA: Utilizarea de rutina a ultrasunetelor in scop diagnostic. In: Tratat de ultrasonografie in obstetrica si ginecologie, a treia editie. Bucuresti, Editura Medicala Amaltea, 2012, pp 45-63

Kupesic- Plavsic S, Patham Bhargavi, Honemeyer U, Kurjak A: Anatomia ecografica a aparatului genital. In: Tratat de ultrasonografie in obstetrica si ginecologie, a treia editie. Bucuresti, Editura Medicala Amaltea, 2012, pp 675-683

Mohomed K: Nonmalignant gynecology in James DK, Steer PJ, Weiner CP, et al. High risk pregnancy: Management options, 3rd Edition. Philadelphia, Elsevier Saunders, 2006: 1258-1258

Munkarah AR, Morris RT, Schimp VL: Malignant disease in James DK, Steer PJ, Weiner CP, et al. High risk pregnancy: Management options, 3rd Edition. Philadelphia, Elsevier Saunders, 2006: 1163-1173

Hoffman M, Sayer R, A guide to management: Adnexal masses in pregnancy, *OBG Management*, vol 19, no3, 2007, p 27-44

Nupur Gupta, VatslaDadhwal, et al, Incidental adnexal masses removed at laparoscopic ligation or caesarean section, *Arch GynecolObstet*, 281, 2010, p 775-776

Leiserowitz GS, Managing Ovarian Masses During Pregnancy, *Obstetrical and Gynecological Survey*, vol 61, no7, 2006, p 463-470

Whitecar MP, Turner S, Higby MK. Adnexal masses in pregnancy. A review of 130 cases undergoing surgical management.*AmJ ObstetGynecol*; 181, 1999, p19–24.

Platek DN, Henderson CE, Goldberg GL.The management of a persistent adnexal mass in pregnancy.*Am J ObstetGynecol*, 173, 1995, p1236-1240

Hoffman M, Sayer R, A guide to management: Adnexal masses in pregnancy, *OBG Management*, vol 19, no3, 2007, p 27-44

Nupur Gupta, Vatsla Dadhwal, et al, Incidental adnexal masses removed at laparoscopic ligation or caesarean section, *Arch GynecolObstet*, 281, 2010, p 775-776

Leiserowitz GS, Managing Ovarian Masses During Pregnancy, *Obstetrical and Gynecological Survey*, vol 61, no7, 2006, p 463-470

Whitecar MP, Turner S, Higby MK. Adnexal masses in pregnancy. A review of 130 cases undergoing surgical management.*AmJ ObstetGynecol*; 181, 1999, p19–24.

Platek DN, Henderson CE, Goldberg GL.The management of a persistent adnexal mass in pregnancy.*Am J ObstetGynecol*, 173, 1995, p1236-1240

Hermans RHM, Fischer D-C, van der Putten HWHM, et al. Adnexal masses in pregnancy. *Onkologie*.26, 2003, p167–172.

Agarwal N, Parul, Kriplani A, Bhatla N, Gupta A. Management and outcome of pregnancies complicated with adnexal masses. *Arch Gynecol Obstet*.;267, 2003, p148–152.

Schmeler KM, Mayo-Smith WW, Peipert JF, Weitzen S, Manuel MD, Gordinier ME., Adnexal masses in pregnancy: surgery compared with observation. *Obstet. Gynecol*., vol 105, 2005, p1098–1103

Hill LM, Connors-Beatty DJ, Nowak A, Tush B. The role of ultrasonography in the detection and management of adnexal mass during the second and third trimesters of pregnancy.*Am J Obstet Gynecol.* 179, 1998, p703–707.

Koo YJ, Kim TJ, Lee JE, et al, Risk of torsion and malignancy by adnexal mass size in pregnant women, *ActaObstetGynecolScand*, vol 90, 2011, p358-361

Nowak M, Szpakowski M, Wilcznyski JR, Ovarian tumours in pregnancy- proposals for diagnosis and treatment, *Ginekol Pol*, 75, 2004, p242-249

Arteaga-Gomez AC, Aranda-Flores C, Marquez-Acosta, et al, Adnexal tumor and pregnancy: diagnosis and treatment, *GinecolObstetMex*, vol 78, no 3, 2010, p 160-167

Horowitz NS, Management of adnexal masses in pregnancy, *ClinObstetGynecol*, vol 54, no 4, 2011, p 519-527

Corresponding author: Associate Professor Furău Gheorghe,
No 2, Romei Street, Arad, Arad County, PO: 310057;
Tel: + 40 722 483640
Email: gfurau@gmail.com